

Details of a Tendon–Sparing Posterior Approach in Hemiarthroplasty in the Treatment of Displaced Intracapsular Neck of Femur Fracture

Paul YF Lee^{1*}, John Charity¹ and John Timperley^{1,2}

¹Exeter Hip Unit, Princess Elizabeth Orthopaedic Centre, Royal Devon and Exeter NHS Foundation Trust, Exeter, UK

²College of Engineering, Maths and Physical Science, University of Exeter, Exeter, UK

*Corresponding author: Paul YF Lee, Exeter Hip Unit, Princess Elizabeth Orthopaedic Centre, Royal Devon and Exeter NHS Foundation Trust, Exeter, UK, Tel: +447764614688; E-mail: paullee1@nhs.net

Received date: June 16, 2017; Accepted date: June 17, 2017; Published date: June 22, 2017

Copyright: © 2017 Lee PYF, et al. This is an open-access article distributed under the terms of the Creative Commons Attribution License, which permits unrestricted use, distribution, and reproduction in any medium, provided the original author and source are credited.

Abstract

This paper details a tendon–sparing surgical technique allowing hemiarthroplasty through a posterior approach in all cases whilst preserving the Quadriceps coxa. The SPAIRE (Sparing Piriformis and Internus, Repair Externus) technique, described by Hanly et al. for routine use in total hip replacement, theoretically offers the functional benefits of the posterior approach with reduced risk of dislocation. It may also facilitate early mobilisation after hip fracture surgery with potential reduction in medical complications and mortality. In this study, we report our initial experience using the same SPAIRE technique for hemiarthroplasty to treat all patients with displaced intracapsular neck of femur fractures, irrespective of skeletal dimension and BMI. Our results suggest that the SPAIRE technique is feasible and safe to be used in all cases requiring hemiarthroplasty. Further research should be encouraged to investigate the role of the SPAIRE technique in fractured neck of femur surgery.

Keywords: SPAIRE; Fracture neck of femur; Intracapsular fracture; Hemiarthroplasty; Hip replacement; Tendon sparing; Quadriceps coxa

Introduction

Hemiarthroplasty of the hip is the treatment of choice recommended by the National Institute for Health and Care Excellence (NICE) for a subgroup of elderly patients with a displaced intracapsular neck of femur fracture [1].

The most commonly used approach for hemiarthroplasty in the UK is the direct lateral approach [2,3] popularised by Hardinge in 1982 [4]. This approach involves section or detachment of part of the gluteus medius and minimus tendons in order to gain access to the hip joint. Although the abductors are repaired later with strong sutures, most patients will experience abductor weakness, certainly initially, and this is likely to affect immediate post-operative recovery.

The posterior approach, as described by Austin Moore in 1957 [5] has been used by some surgeons in order to preserve the abductor complex. This approach has resulted in better patient-reported outcomes as demonstrated by the Norwegian and Swedish Hip Fracture Registers [2,3]. However, the posterior approach is associated with a significantly higher dislocation rate [3]. Patients who undergo hemiarthroplasty are usually frail and it is important to minimise the risk of complications and the need for further operative interventions. Dislocation following hemiarthroplasty can significantly reduce the quality of life of patients suffering this complication and is associated with poor outcome [6,7]. In patients suffering a neurological disorder who underwent hemiarthroplasty, Han et al reported a reduced incidence of dislocation using a minimally invasive posterior approach preserving the external rotators. We believe this was the first description of an approach through this interval for hemiarthroplasty [8]. Han suggested that the approach may only be suitable for Asian patients with low BMI and smaller skeletal structures.

We describe in this paper details of our surgical technique allowing hemiarthroplasty through a posterior approach in all cases whilst preserving the Quadriceps coxa [9]. This technique has been described for routine use in total hip replacement [10]. Hanly describes in detail the relevant anatomy and steps necessary to safely avoid the abductor complex as well as preserving both gemelli, obturator internus and piriformis tendons [10]. The technique for total hip arthroplasty has been described as “SPAIRE” (Sparing Piriformis and Internus, Repair Externus), and theoretically offers the functional benefits of the posterior approach with reduced risk of dislocation. It may also facilitate early mobilisation after hip fracture surgery with potential reduction in medical complications and mortality [11].

In this study, we report our initial experience using the same SPAIRE technique for hemiarthroplasty to treat all patients with displaced intracapsular neck of femur fractures, irrespective of skeletal dimension and BMI.

Materials and Methods

Between 1st September 2016 and 28th February 2017, prospective data was collected in all consecutive patients who underwent hemiarthroplasty for neck of femur fracture in a single centre. Surgical approach, age, gender, American Society of Anesthesiologists (ASA) grade, pre-fracture mobility, Abbreviated Mental Test Score (AMTS) as well as place of residence before admission and discharge were recorded.

SPAIRE hemiarthroplasties were performed by the specialist hip team consultants, the associate specialist, Hip Fellows and by registrars after training by the senior hip surgeons. The Direct lateral approach was performed by other orthopaedic and trauma consultants, associate specialists, fellows and registrars on the ‘on-call’ rota.

SPAIRE Technique in Brief

The patient is positioned in the lateral decubitus position with routine posterior approach skin incision. The interval between quadriceps coxa (QC) and quadratus femoris (QF) is identified and dissected. Trochanteric branches of the medial circumflex artery are cauterised and divided. A bent Hohman-type retractor is introduced around the posterior capsule over the superior femoral neck at all times deep to the Quadriceps coxa.

This manoeuvre is facilitated by the assistant lifting the knee and abducting the flexed hip. Any adhesions can be released by blunt dissection or with fine scissors. The posterior capsule and Obturator Externus (the only tendon divided) and QF are detached from the base of the femoral neck with the proximal extent of the incision running along the femoral neck and through the labrum to the rim of the acetabulum to enter the hip joint (Figure 1).

A strong non-absorbable suture is passed through the obturator externus and posterior capsule in order to help protect the sciatic nerve, allow retraction and later facilitate intraosseous closure. The femur is fully flexed and internally rotated so that the fractured neck becomes exposed beneath the intact group of short external rotators. The surgeon can now perform a safe femoral neck osteotomy and all proximal femoral neck fragments are cleared from any residual capsular attachments and removed. During osteotomy, care is taken not to damage the insertion of the short external rotators on the inside of the greater trochanter. The femoral head is removed with a cork screw head remover; a self-retainer with offset limbs retracting between the posterior capsule and trochanter helps inspection of the acetabulum and facilitates removal of head fragment and ligamentum teres. With the hip held in a flexed and fully internally rotated position, an accurate slot is developed in the cancellous bone in the femoral neck in the desired angle of anteversion.

Since Piriformis and Obturator Internus are inserted anteriorly and proximally to the planned femoral slot they can be preserved without release from the trochanter. Use of a high speed burr as part of the technique is useful to remove the remaining lateral cortex of the femoral neck angling beneath the QC (Figure 2). During broaching of the femur, take care not to injure the musculature during preparation of the femoral slot. The femoral component is cemented into the femur with modern cementing technique taking all the precautions advised by the BCIS working group [12]. After the Cement has set, the hemiarthroplasty is reduced into the acetabulum by fully flexing and then carefully externally rotating the hip whilst continually applying traction in order to pass the head beneath the short external rotators without damaging them. An enhanced transosseous capsular repair is performed at the end of the procedure by passing the strong non-absorbable stay suture through 2.5 mm drill holes made along the posterior third of the greater trochanter repairing the capsule and obturator externus tendon as close as possible to their anatomical positions. Further details of the SPAIRE technique for total hip replacement are described by Hanly et al. [10].

Results

During the 6 months period, 110 consecutive patients underwent hemiarthroplasty for neck of femur fractures; 85 patients had a direct lateral approach and 25 patients had the SPAIRE technique performed. All patients received a taper-slip cemented hemiarthroplasty.

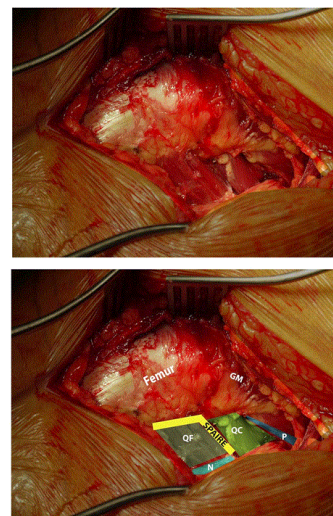


Figure 1: Posterior view of the external rotator complex of the Left hip, patient is in the lateral decubitus position; Interval for the SPAIRE technique is highlighted. GM: Gluteus medius; QC: Quadriceps coxa; QF: Quadratus femoris; P: Piriformis; N: Sciatic Nerve; SPAIRE: Interval between QC and QF.

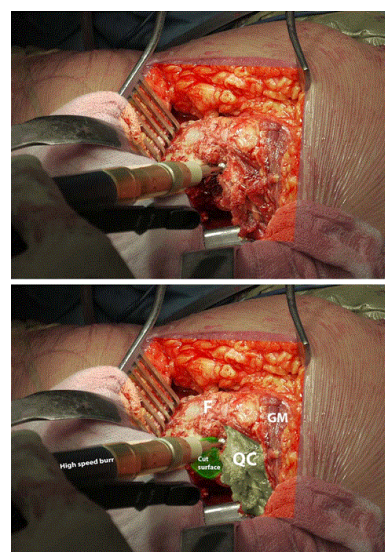


Figure 2: Lateral femoral view- Left hip lateral decubitus position. Surgical photo at the start of the femur preparation using the SPAIRE technique. Femur is flex to 90 degrees and 90 degrees of internal rotation; the fractured end is freshened, shown as 'cut surface'. A High speed burr is used to remove the remaining lateral cortex of the femoral neck. The QC is still attached to the femur view of the external rotator complex of the Left hip; patient is in the lateral decubitus position. GM: Gluteus medius; QC: Quadriceps coxa; F: Femur.

The mean age of all patients was 86.8 and the median ASA grade was 3.52% were right sided and the mean pre op AMTS was 6.4; 81%

of the patients were admitted from their own home or sheltered housing, 14% previously lived in residential care and 5% were from nursing care. There was no significant difference between the SPAIRE and lateral groups in age, ASA grades, admission location, post op discharge destination or AMTS (Table 1). The mean number of days from admission to discharge was one day less in the SPAIRE group compared to the lateral group, although it is not statistically significant (Table 2). There were no dislocations in either group during the study period.

	Lateral	SPAIRE
Mean Age	86.5	87.7
range	62-100	67-100
SD	6.96	7.87
Age Group		
<70	4%	4%
71-80	12%	16%
81-90	47%	36%
90+	38%	44%
Side		
Left	51%	36%
Right	49%	64%
Gender		
Male	33%	60%
Female	67%	40%
ASA		
Median ASA	3	3

Table 1: General demographic data for both groups.

	Lateral	SPAIRE
Pre op location		
Own home/sheltered housing	81%	80%
Nursing care	7%	0%
Residential care	12%	20%
Post op location		
Own home/sheltered housing	21%	24%
Rehabilitation hospital bed	58%	56%
Nursing care	7%	4%
Residential care	9%	16%
Deceased	5%	0%
Pre and Post location		
Different	65%	60%

Same	35%	40%
Mean days to discharge	9.96	8.94
Range	Jan-66	Jan-23
SD	9.88	6.21
Mean AMTS		
AMTS Pre op	6	7
AMTS Post op	6	7

Table 2: Pre and post op data for Lateral and SPAIRE groups.

Discussion

Early mobilization following hip fracture surgery reduces medical complications and mortality [1-3,6,10]. The patients in the SPAIRE group in this study were discharged one day earlier compared to the lateral group. Although this effect could be due to multiple factors and was not statistically significant, it provided initial data for power calculations.

In order to provide 80% power with the mean difference of one day, total of 1041 patients will be needed. In order to fully understand the impact of using the SPAIRE approach for hemiarthroplasty, a randomised control trial is currently in the planning with our department (Table 3).

Age	Gender	AMTS pre-op	ASA	Days to discharge	Transfusion	Return to Theatre
90	Male	9	3	10	no	none
100	Male	1	3	13	no	none
90	Female	10	3	5	no	none
91	Female	0	3	23	no	none
85	Male	10	3	1	no	none
71	Female	9	3	1	no	none
97	Female	2	3	3	no	none
87	Male	9	3	6	no	none
95	Male	10	3	6	no	none
80	Female	4	3	3	no	none
88	Male	10	4	17	no	none
67	Male	10	4	11	no	none
94	Male	10	3	4	no	none
89	Male	0	3	14	no	none
91	Female	3	4	4	no	none
91	Female	9	3	7	no	none
76	Male	10	3	6	no	none
90	Male	9	3	21	no	none

81	Female	10	3	6	no	none
83	Male	8	3	10	no	none
88	Male	9	2	10	no	none
91	Male	10	3	20	no	none
89	Male	9	3	6	no	none
94	Female	10	2	9	no	none
95	Female	8	3	3	no	none

Table 3: All SPAIRE hemi arthroplasty patients.

A tendon sparing posterior technique offers theoretically a better chance for early post-operative mobility in terms of protecting the abductor mechanism, it also preserves the OI tendon which acts as a check rein to prevent posterior dislocation. Damage to the Quadriceps coxa is reduced by using a high speed burr to develop a slot in the trochanter behind the insertions of Piriformis and Obturator Internus. The strong transosseous capsular repair of Obturator Externus with the posterior capsule further reinforces stability. This study is the first to report that it is feasible to use the SPAIRE technique to perform cemented hemi arthroplasty with straight Exeter stems to treat Intracapsular neck of femur fractures in an unselective fashion. There has not been any intraoperative or post-operative complication with this initial group of patients.

The lateral approach involves the detachment and repair of the anterior part of gluteus medius and that of gluteus minimus [4], which can affect the function of the muscles by intraoperative overstretching and iatrogenic denervation [12,13].

The SPAIRE technique allows preservation the piriformis tendon as well as the conjoint insertion of obturator internus and the gemelli. These muscles work synergistically as the primary abductor and extensor of the flexed hip; they are referred to as quadriceps coxa by Vaarbakken et al. [9]. It concludes that the quadriceps coxa is not just an external rotator but is also the primary abductor and extensor for the hip joint in a 90° flexed position. The quadriceps coxa also has a major effect on one-legged and weight-bearing rising and propulsive motions [9]. These are essential every time a patient is trying to get up from a seated position in a chair. Similar findings with the function of the quadriceps coxa have also been reported by Lee et al. when each trochanteric muscle was analysed by a string and computer based model [14]. This confirmed that the piriformis, obturator internus and the gemelli complex play an essential role when the hip is flexed between 60-90°.

In terms of surgical significance of the quadriceps coxa, Kim et al. [15] and Hanly et al. [10] have reported increased intra operative stability of total hip replacement when the external rotators are preserved. Kim reported significant reduction in the dislocation rate compared to sectioning and repairing the external rotators and capsule in their 220 case series of total hip replacement in patients the majority of whom had AVN and relatively low BMI [15]. Hanly et al. also reported initial success with the SPAIRE technique for over 100 consecutive patients in total hip replacements with cemented stems for all diagnoses [10]. With regards to the treatment of neck of femur fractures and hemiarthroplasty, Han et al reported good results with the use of external rotator sparing technique in their series of bipolar cementless hemiarthroplasty in patients with neurological disorder [8].

The limitation of our prospective case series is due to the small number of patients and selection has not been randomised. SPAIRE hemiarthroplasties were performed by the specialist hip surgeons in a specialist centre. The Direct lateral approach was performed by a mix of orthopaedic and trauma surgeons. Nevertheless, our study demonstrated the feasibility of using the SPAIRE technique for hemiarthroplasty to treat all patients with displaced Intracapsular neck of femur fractures, irrespective of anatomy and BMI.

Conclusion

A further study is currently on the way to investigate the role of the SPAIRE technique in fracture neck of femur surgery. Nevertheless, this study suggests that the SPAIRE technique is feasible and safe to be used in all cases requiring hemiarthroplasty after training in the technique.

References

- Swift C, Ftouh S, Langford P, Chesser TS, Johanssen A (2016) Interdisciplinary management of hip fracture. *Clin Med (Lond)* 16: 541-544.
- Kristensen TB, Vinje T, Havelin LI, Engesaeter LB, Gjertsen JE (2017) Posterior approach compared to direct lateral approach resulted in better patient-reported outcome after hemiarthroplasty for femoral neck fracture. *Acta Orthop* 88: 29-34.
- Leonardsson O, Rolfson O, Rogmark C (2016) The surgical approach for hemiarthroplasty does not influence patient-reported outcome: a national survey of 2118 patients with one-year follow-up. *Bone Joint J* 98-B(4): 542-547.
- Hardinge K (1982) The direct lateral approach to the hip. *J Bone Joint Surg Br* 64: 17-19.
- Moore AT (1957) The self-locking metal hip prosthesis. *J Bone Joint Surg Am* 39-A(4): 811-827.
- Enocson A, Pettersson H, Ponzer S, Tornkvist H, Dalen N, et al. (2009) Quality of life after dislocation of hip arthroplasty: a prospective cohort study on 319 patients with femoral neck fractures with a one-year follow-up. *Qual Life Res* 18: 1177-1184.
- Leonardsson O, Karrholm J, Akesson K, Garellick G, Rogmark C (2012) Higher risk of reoperation for bipolar and uncemented hemiarthroplasty. *Acta Orthop* 83: 459-466.
- Han SK, Kim YS, Kang SH (2012) Treatment of femoral neck fractures with bipolar hemiarthroplasty using a modified minimally invasive posterior approach in patients with neurological disorders. *Orthopedics* 35: e635-e640.
- Vaarbakken K, Steen H, Samuelsen G, Dahl HA, Leergaard TB, et al. (2014) Lengths of the external hip rotators in mobilized cadavers indicate the quadriceps coxa as a primary abductor and extensor of the flexed hip. *Clin Biomech (Bristol, Avon)* 29: 794-802.
- Hanly RJ, Sokolowski S, Timperley AJ (2017) The SPAIRE technique allows sparing of the piriformis and obturator internus in a modified posterior approach to the hip. *Hip Int* 27: 205-209.
- Kronborg L, Bandholm T, Palm H, Kehlet H, Kristensen MT (2016) Physical Activity in the Acute Ward Following Hip Fracture Surgery is Associated with Less Fear of Falling. *J Aging Phys Act* 24: 525-532.
- Griffiths R, White SM, Moppett IK, Parker MJ, Chesser TJ, et al. (2015) Safety guideline: reducing the risk from cemented hemiarthroplasty for hip fracture 2015: Association of Anaesthetists of Great Britain and Ireland British Orthopaedic Association British Geriatric Society. *Anaesthesia* 70: 623-626.
- Siebenrock KA, Rösler KM, Gonzalez E, Ganz R (2000) Intraoperative electromyography of the superior gluteal nerve during lateral approach to the hip for arthroplasty. *J Arthroplasty* 15: 867-870.
- Lee YC, Callary SA, Howie DW, Thewlis D, Solomon LB (2012) The Effect of Hip Position on the Length of Trochanteric Muscles: Potential

- Implications for Early Postoperative Management of Hip Arthroplasty. *J Arthroplasty* 27: 953-960.
15. Kim YS, Kwon SY, Sun DH, Han SK, Maloney WJ (2008) Modified posterior approach to total hip arthroplasty to enhance joint stability. *Clin Orthop Relat Res* 466: 294-299.